PoCUS and Literature

Inseparable Triple

Heart, Lung and IVC

Betül Evren Gülalp

2014

ELSEVIER

The American Journal of Emergency Medicine

Volume 31, Issue 8, August 2013, Pages 1208-1214

Original Contribution

Diagnosing heart failure among acutely dyspneic patients with cardiac, inferior vena cava, and lung ultrasonography ☆ ☆☆ ★

Kenton L. Anderson MD [a], Katherine Y. Jenq MD [b], J. Matthew Fields MD [a], Nova L. Panebianco MD [a], Anthony J. Dean MD [a]

- Prospective and cohort
- Dyspneic patients
- Differential dx

Emergency Sonologists

Cutoff for Acute Decomp. Heart Failure

- LVEF < 45%,
- IVC-CI < 20%, and
- At least 10 B-lines.

RESULTS

- 44% had ADHF.
- Sensitivity and specificity (95% CI) for the presence of ADHF were;
- 74 and 74 by using LVEF less than 45%,
- 52 and 86 by using IVC-CI less than 20%,
- 70 and 75 by using B-lines at least 10.

Inter-Rater Reliability of Quantifying Pleural B-Lines Using Multiple Counting Methods

Kenton L. Anderson, MD, J. Matthew Fields, MD, Nova L. Panebianco, MD, Katherine Y. Jenq, MD, Jennifer Marin, MD, MSc, Anthony J. Dean, MD

Examines 3 methods of quantifying B-lines for inter-rater reliability.

- Sonographic B-lines= Sign of

  Increased extravascular lung water
- Several techniques for quantifying B-lines
- Different methods for "scoring" the cumulative B-line counts

- Dyspnea + suspected Acute Heart Failure

RESULTS:

- 456 video clips
- Correlation Coefficients (95% CI) for 3 different methods;
- 0.84, 0.87, and 0.89
- While, p = .003 comparing methods 1 and 3.

- 1, B-lines counted over an entire respiratory cycle;
- 2, As per method 1, but confluent B-lines are counted as multiple based on the percentage of the rib space they occupy,
- **3, As per method 2, but the count is made at the moment when the most B-lines are seen, not over an entire respiratory cycle**

- All methods of B-line quantification were substantial inter-rater agreement.
- Method 3 is more reliable.

Kajimoto *et al. Cardiovascular Ultrasound* 2012, **10**:49
http://www.cardiovascularultrasound.com/content/10/1/49

CARDIOVASCULAR ULTRASOUND

RESEARCH **Open Access**

Rapid evaluation by lung-cardiac-inferior vena cava (LCI) integrated ultrasound for differentiating heart failure from pulmonary disease as the cause of acute dyspnea in the emergency setting

Katsuya Kajimoto[1*], Keiko Madeen[1], Tomoko Nakayama[2], Hiroki Tsudo[3], Tadahide Kuroda[1] and Takashi Abe[3]

- Rapid and accurate diagnosis and management is lifesaving for patients with Acute Dyspnea.

- Evaluation of PoCUS;
- **Lung+Cardiac+Inferior Vena Cava**

- 90 patients,
- In 30 minutes of admission

RESULTS:

The final diagnosis was acute dyspnea due to;

- AHFS, 53 patients,
- Pulmonary Disease despite a history of heart failure, 18 patients,
- Pulmonary Disease, 19 patients.

- + IVC US ‘s sensitivity, specificity, negative predictive value, and positive predictive value
- = 94.3, 91.9, 91.9, and 94.3%

CONCLUSIONS:

- Rapid evaluation of IVC US is extremely accurate in differentiating of acute dyspnea due to AHFS from that caused by primary pulmonary disease in the emergency setting.

Radiol med (2013) 118:196–205
DOI 10.1007/s11547-012-0852-4

CHEST RADIOLOGY
RADIOLOGIA TORACICA

Lung ultrasound in diagnosing and monitoring pulmonary interstitial fluid

Ecografia polmonare nella diagnosi e nel monitoraggio dei fluidi interstiziali polmonari

G. Volpicelli[1] • L.A. Melniker[2] • L. Cardinale[3] • A. Lamorte[1] • M.F. Frascisco[1]

[1]Department of Emergency Medicine, San Luigi Gonzaga University Hospital, Torino, Italy
[2]Department of Emergency Medicine, New York Methodist Hospital, NY, USA
[3]Institute of Radiology, San Luigi Gonzaga University Hospital, Torino, Italy
Correspondence to: L. Cardinale, S.C.D.U. Radiologia, Ospedale San Luigi Gonzaga, Regione Gonzole 10, Orbassano, 10040 Torino, Italy, e-mail: luciano.cardinale@gmail.com

Decompensated heart failure

- The redistribution of fluids into the pulmonary vascular bed
- Leads to respiratory failure,

= A common cause of presentation to the ED.

Lung ultrasound (US) answers to the questions of;

- Pulmonary Interstitial Fluid
- Alveolar Oedema.

- Real-time sonography of the lung determines B-lines artefacts on bedside= Diagnosis of respiratory failure due to impairment of cardiac function,

- **Monitoring the pulmonary interstitial fluid**.

Current Cardiology Reviews, 2012, *8*, 123-136

Lung Ultrasound in the Management of Acute Decompensated Heart Failure

Shiang-Hu Ang[1,*] and Phillip Andrus[2]

[1]*Department of Emergency Medicine, Changi General Hospital, Singapore;* [2]*Department of Emergency Medicine, Mount Sinai School of Medicine, New York, NY. USA*

B-lines= Arise from the pleural

Long along in all image, eliminating by A- lines on respiration.

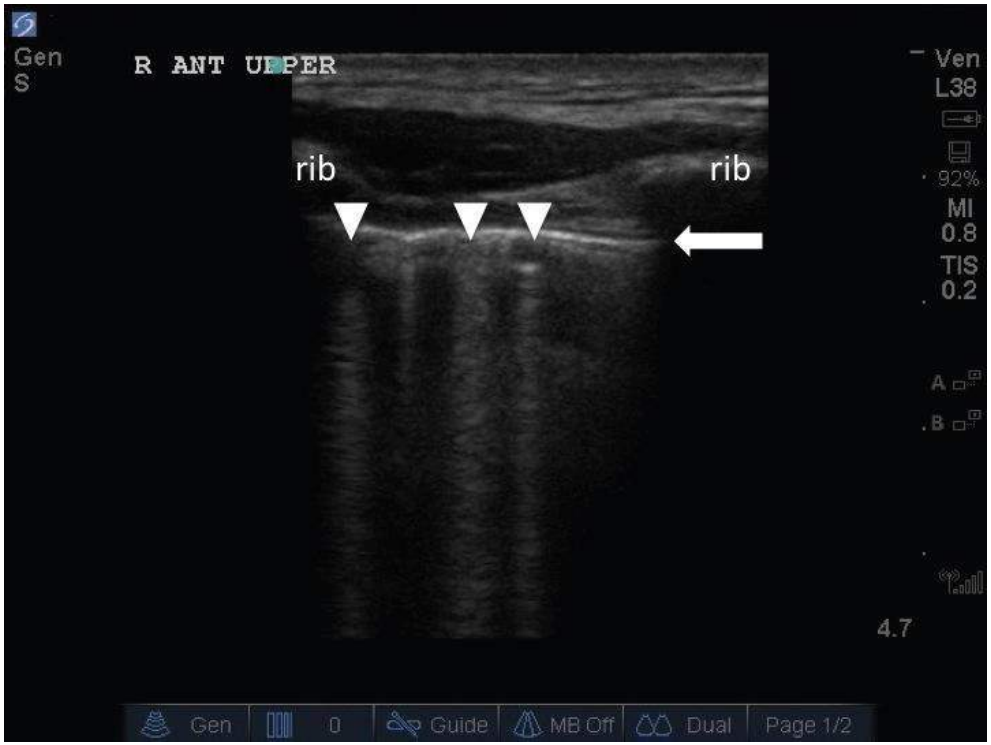

A-lines= Artefacts the pleura and the surface of the chest wall

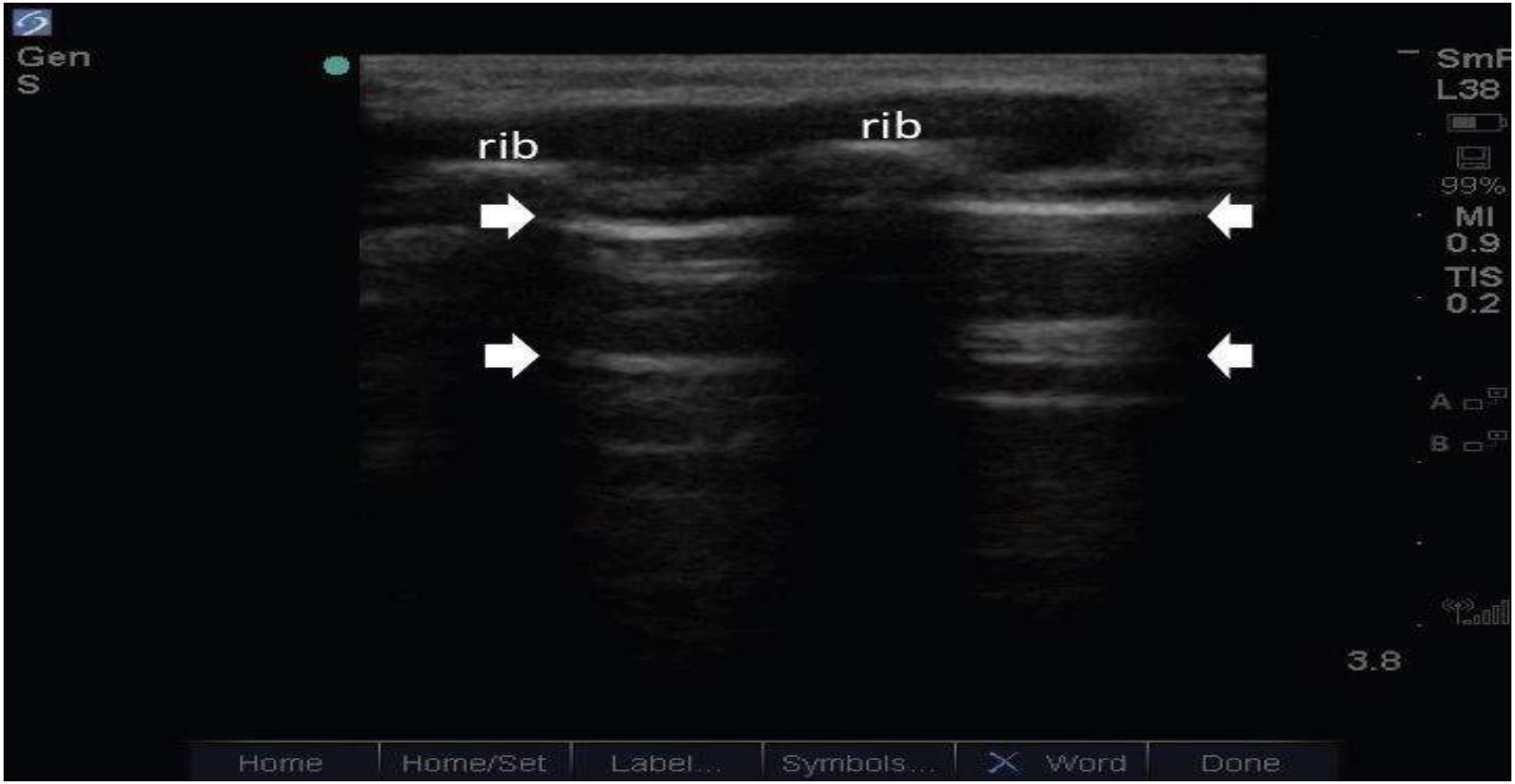

Multiple B-lines separated by 7 mm= Septal Syndrome

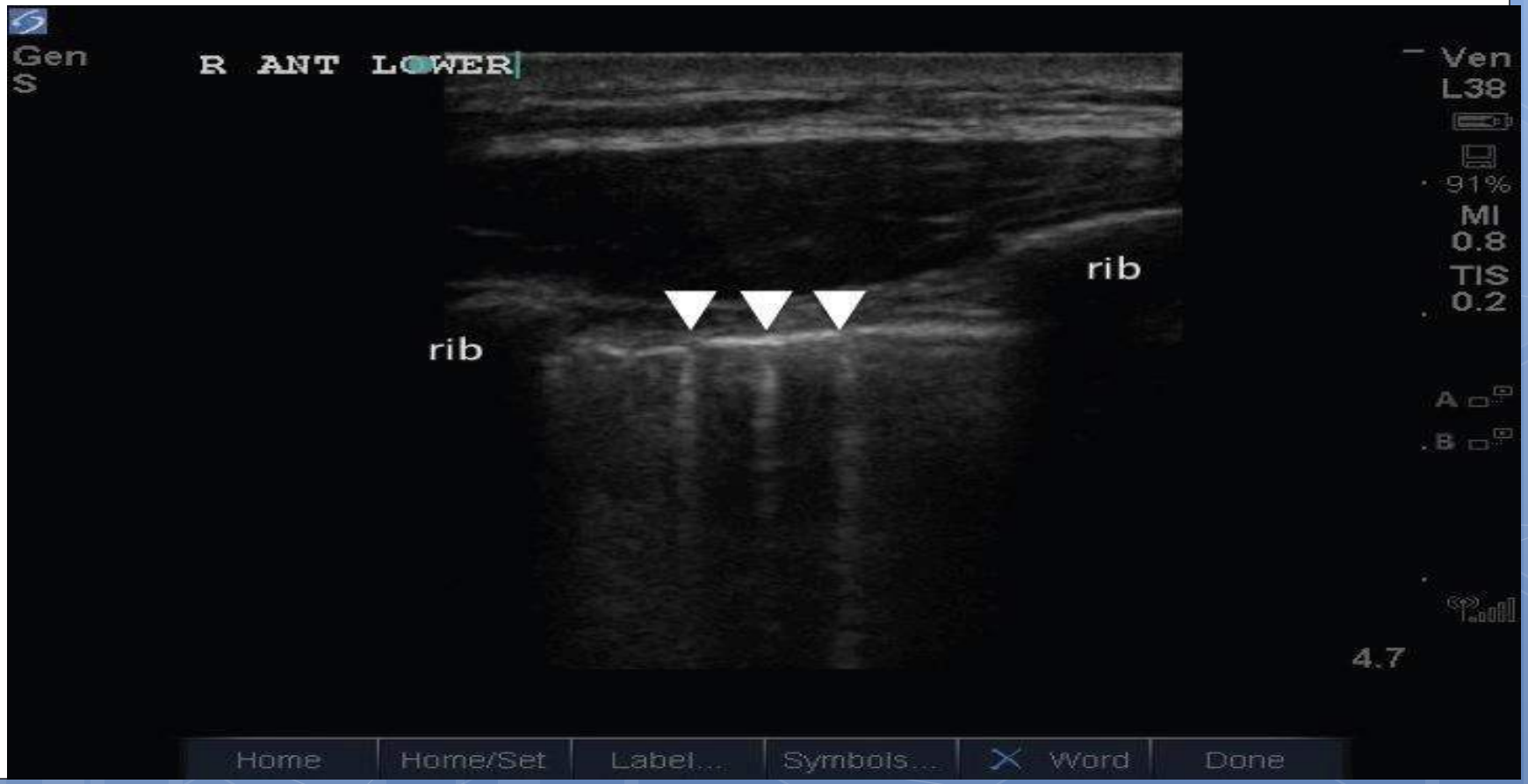

Multiple B lines, as two distinct bands

Confluence of multiple B lines= White Lung

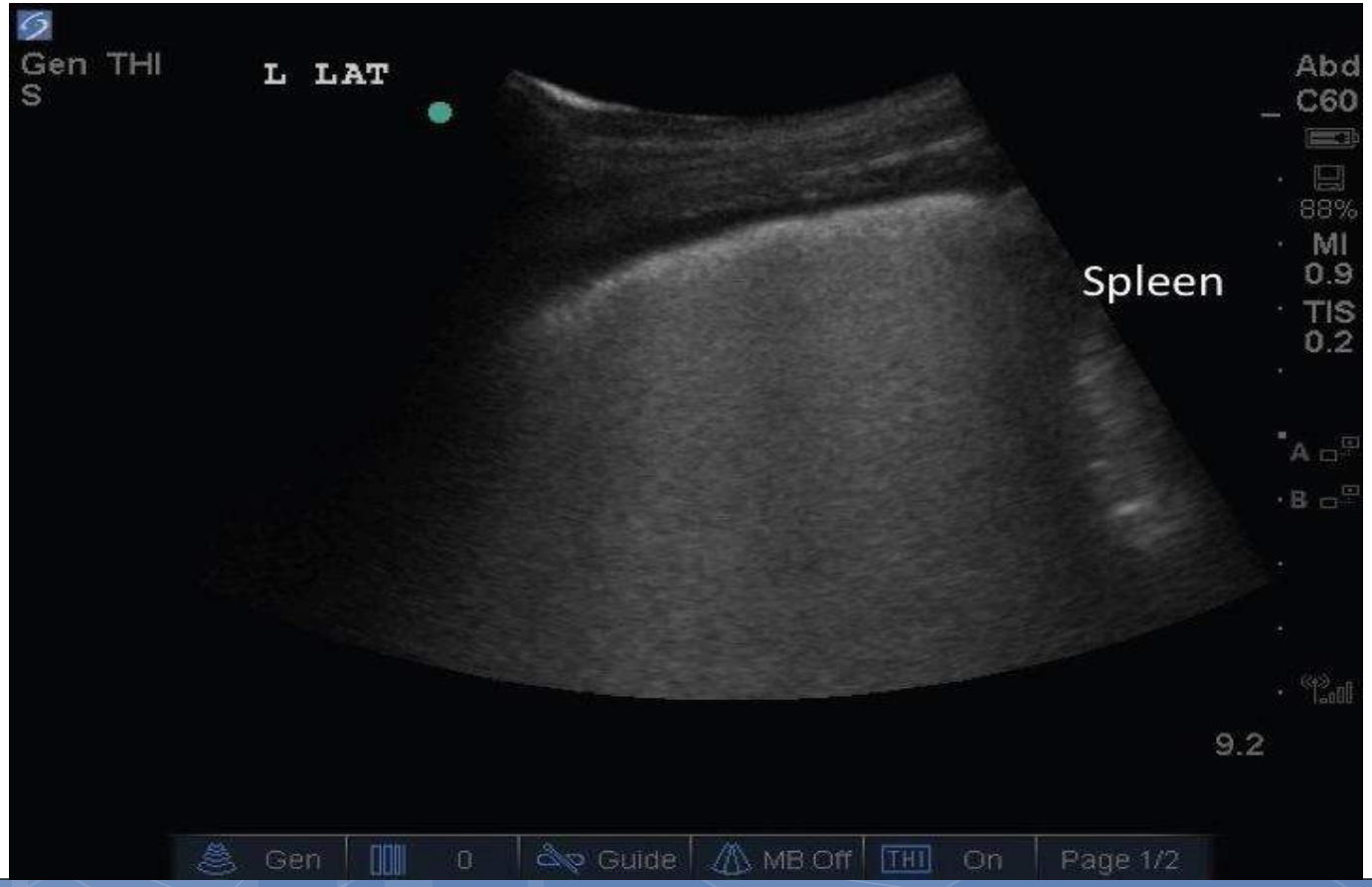

8 Zones on Chest

- Hemichest ;
- Anterior and lateral,
- Upper and lower halves
- Anterior chest = The parasternal and anterior axillary lines,
- Lateral chest= Anterior and posterior axillary lines.

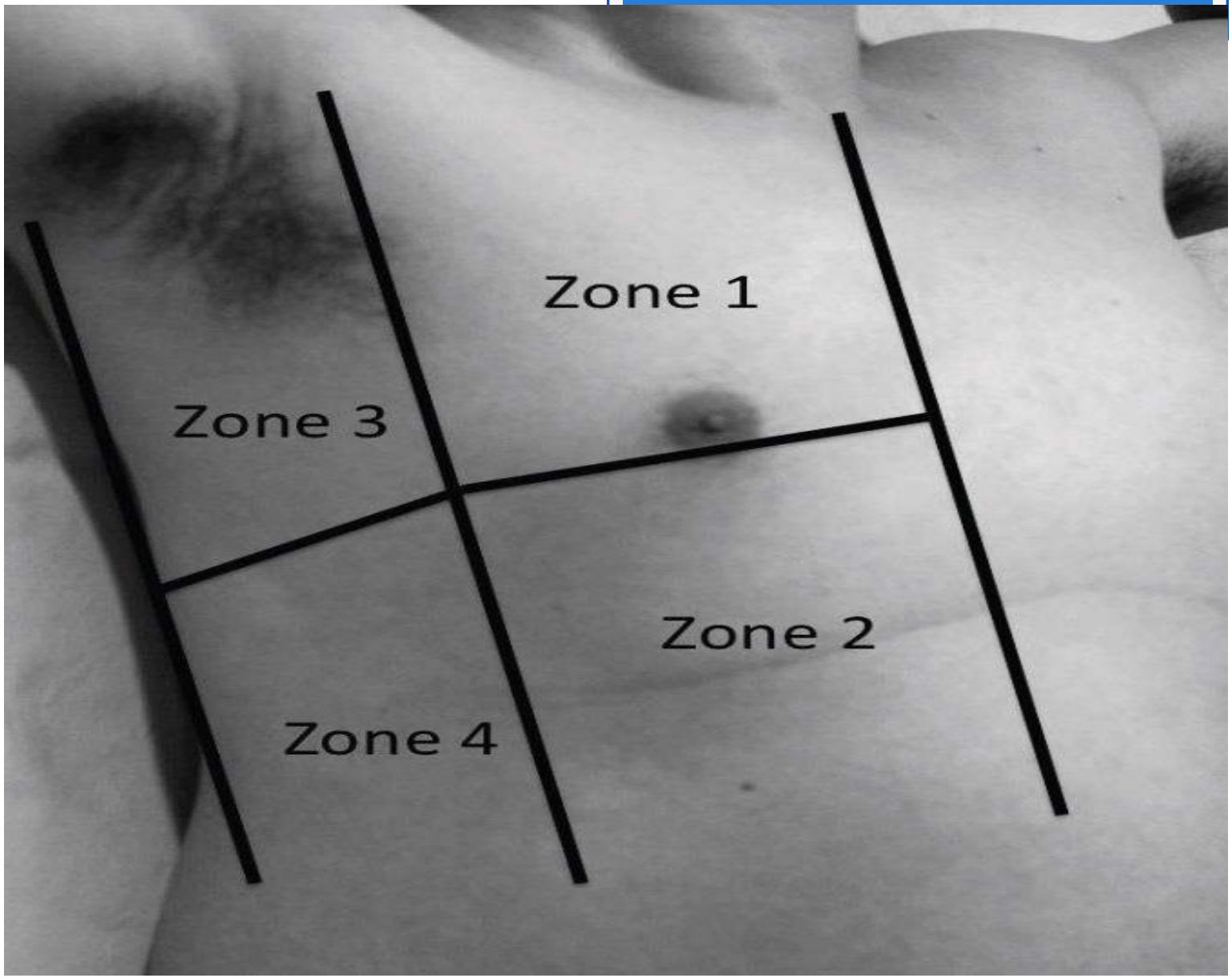
Zone 1
Zone 3
Zone 2
Zone 4

6 Zones for hemichest

- Each hemichest divides
- Anterior,
- Lateral,
- Posterolateral zones.
- Each subdivides ;
- Upper,
- Lower
- *Zone 3= Beyond the posterior axillary line

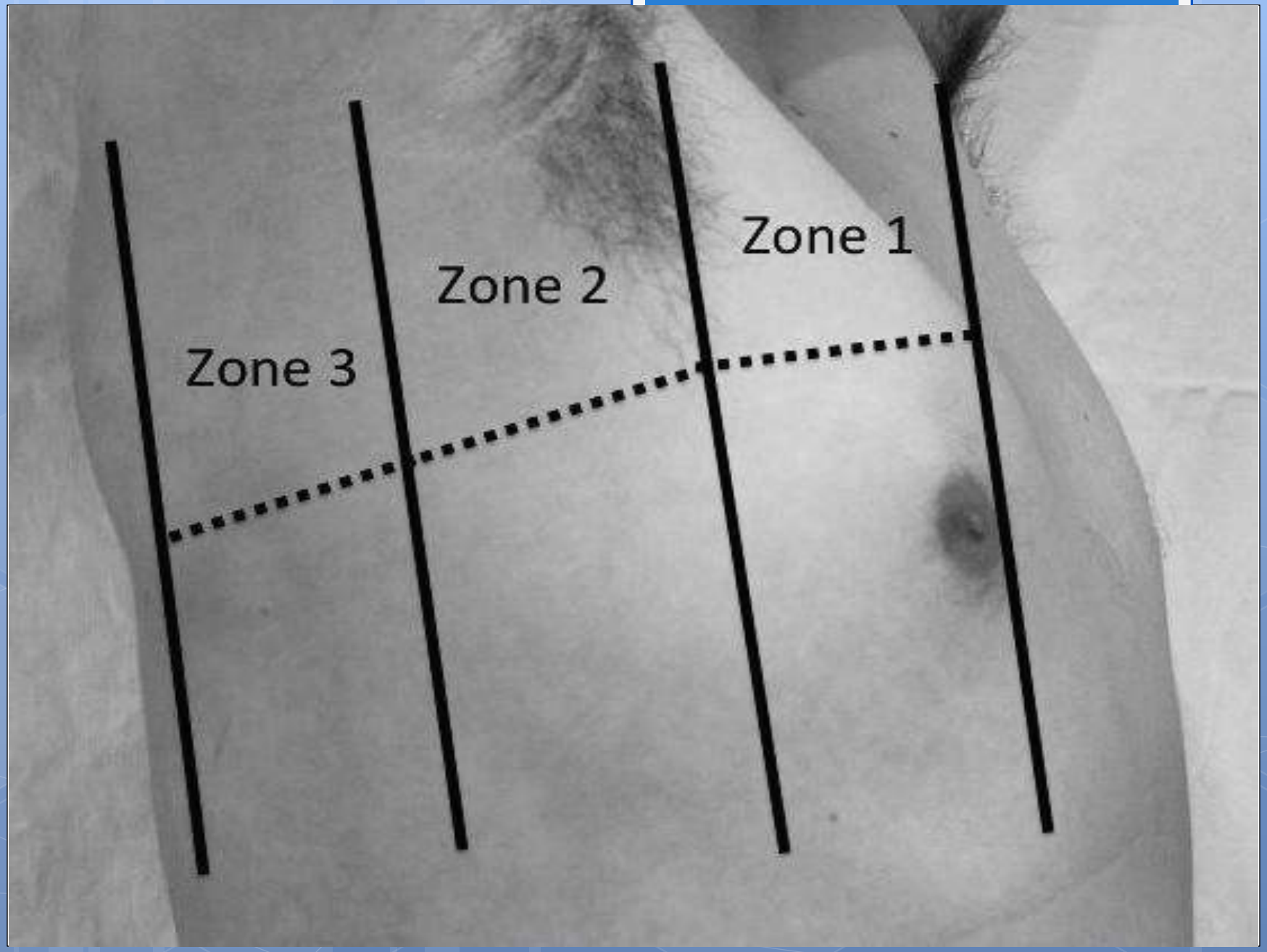
Zone 1
Zone 2
Zone 3

28 Scan Sites: Probe locations

The anterior and lateral chest walls;

- **Parasternal,**
- **Mid-clavicular,**
- **Anterior axillary and**
- **Middle axillary lines,**

RIGHT: 16: 2nd to the 5th intercostal space,

LEFT : 12: 2nd to the 4th intercostal space

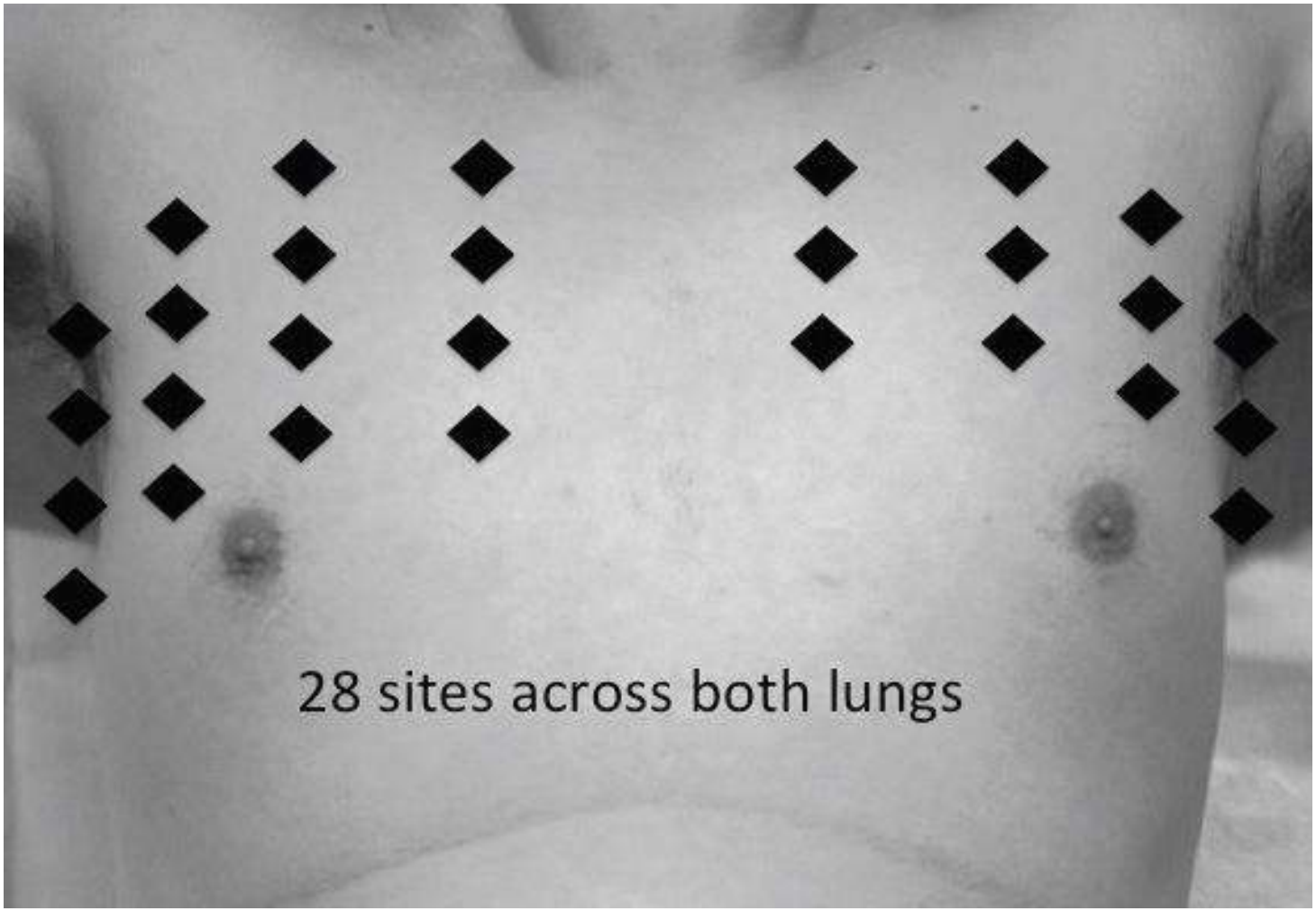
28 sites across both lungs

Reduced lung sliding with pneumonia

Lung Pulses== Small movements of reduced lung sliding= Transmission of cardiac pulsations to the lung on M mode

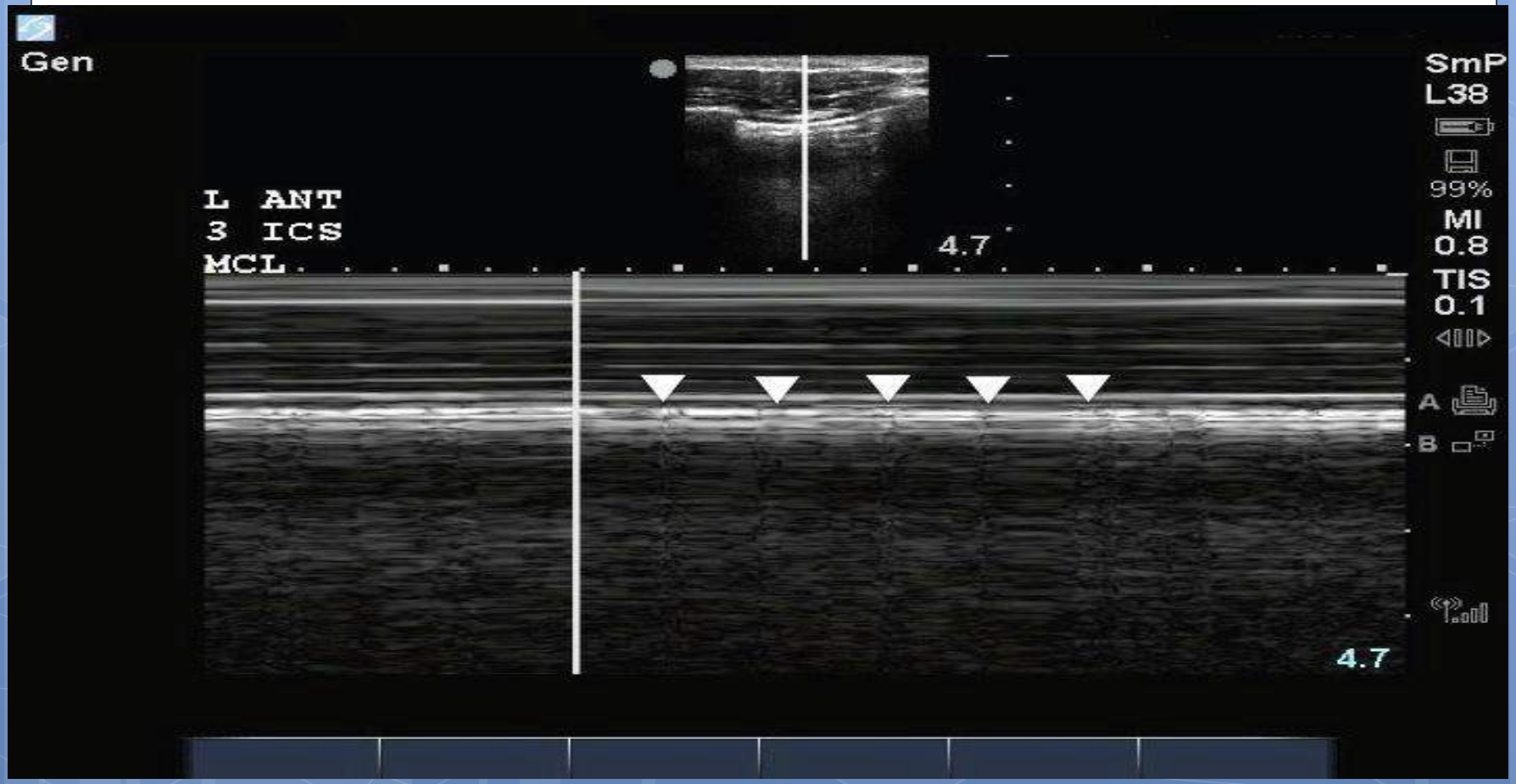

- Appreciate
- Proud of being a member of Emergency Medicine